

# Acute Severe Ulcerative Colitis After mRNA Coronavirus Disease 2019 Vaccination: Can mRNA Vaccines Unmask Inflammatory Bowel Diseases?

Çağatay Ak, MD<sup>1</sup>, Süleyman Sayar, MD<sup>1</sup>, Gupse Adalı, MD<sup>1</sup>, and Kamil Özdil, MD<sup>1</sup>

<sup>1</sup>Department of Gastroenterology, Health Sciences University Umraniye Training and Research Hospital, Istanbul, Turkey

## ABSTRACT

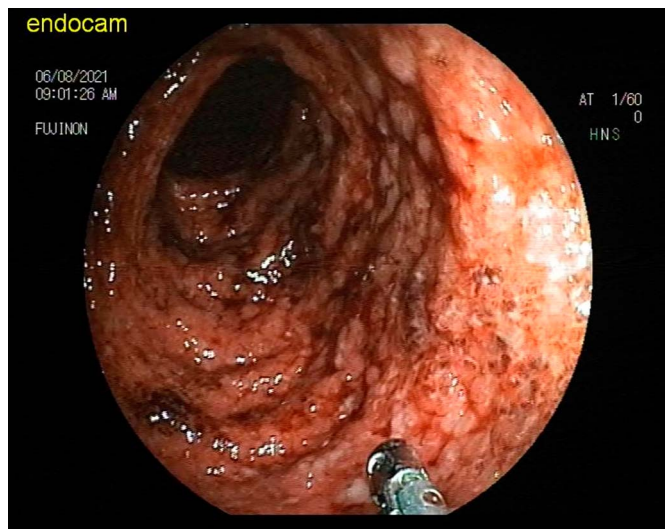
BNT162b2 is a messenger RNA vaccine for the prevention of the novel coronavirus disease 2019 caused by severe acute respiratory syndrome coronavirus 2 infection. The widespread use of this vaccination has brought along several adverse events. We present a patient with newly diagnosed ulcerative colitis after BNT162b2 vaccine.

## INTRODUCTION

The severe acute respiratory syndrome coronavirus 2 (SARS-CoV-2) infection has not been fully controlled yet, and the pandemic of coronavirus disease 2019 (COVID-19) continues to threaten the global public health.<sup>1</sup> Vaccination is generally believed as the most cost-effective intervention to eventually terminate the COVID-19 pandemic by establishing herd immunity among the general population.<sup>2</sup> During the past year, clinically available COVID-19 vaccines have been developed at an unprecedented speed. According to the latest data of World Health Organization, at least 10 kinds of COVID-19 vaccines based on multiple technologies, represented by inactivated vaccine, viral vector vaccine, and messenger RNA (mRNA) vaccine, have been approved for emergency clinical use or conditional marketing.<sup>3</sup> The concept of mRNA vaccines has been scientifically relevant since the early 21st century. The development of the BNT162b2 and mRNA-1273 COVID-19 vaccines presents the initial, large scale, application of this type of inoculation.<sup>4</sup> These vaccines trigger the interferon pathway as part of their mechanism of action, raising concerns about potential safety issues in patients predisposed to autoimmune conditions associated with interferon activation.<sup>5</sup> We present a patient with newly diagnosed ulcerative colitis (UC) after BNT162b2 vaccine.

## CASE REPORT

A 49-year-old man with no history of chronic disease admitted to our outpatient clinic on July 11, 2021, with diarrhea, fever, and weight loss, which started after the second dose of BNT162b2 vaccine. His medical history was unremarkable, and he did not take herbal remedies or other drugs. He had no recent travel history. The patient had 8-10 bloody stools per day and fever for 2 weeks, which started 2 days after the second dose of the vaccination. On physical examination, the patient had a fever of 38.1 °C and widespread tenderness in the abdomen. In the laboratory tests, leukocytes: 12,890 u/L, hemoglobin: 15.3 g/dL, platelets: 431,000 U/L, C-reactive protein: 65.68 mg/L (upper limits of normal 5 mg/L), sedimentation 69 mm per hour, *Clostridium difficile* toxin A and B, enteric adenovirus antigen, *Cryptosporidium* antigen, *Entamoeba histolytica* antigen, and direct microscopic examination of stool revealed no features other than the presence of erythrocytes and leukocytes. Stool culture was unremarkable. Colonoscopic examination showed a normal terminal ileum and the rest of the colon showed findings compatible with ulcerative pancolitis Mayo Score 3 (marked erythema, erosions, ulceration, spontaneous bleeding and submucosal vascular pattern were absent [Figure 1]). Biopsies were taken from all colonic segments, and histopathologic examination showed epithelitis, cryptitis, crypt abscess, architectural damage, and crypt atrophy (Figures 2 and 3). The patient was started 80 mg intravenous methylprednisolone treatment. On the third day of the treatment, the number of daily defecations decreased to 3, and the C-reactive protein value decreased to 22.1 mg/L. The patient was considered as acute severe UC responsive to steroid therapy. After 5 days, he had switched to oral

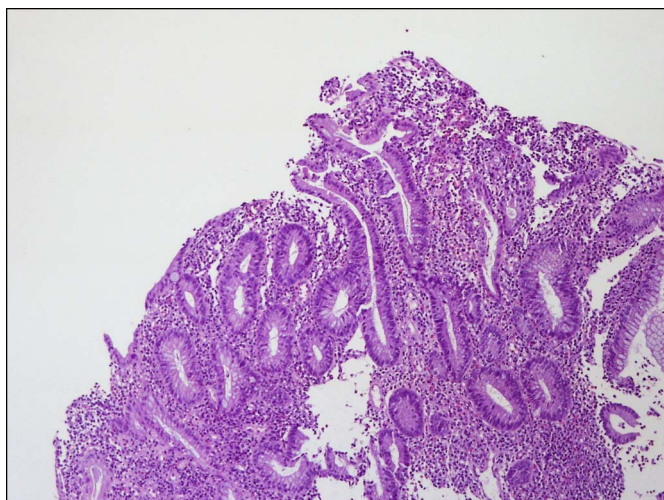


**Figure 1.** Colonoscopy examination; erythema, erosions, ulceration, spontaneous bleeding, and submucosal vascular pattern appearance.

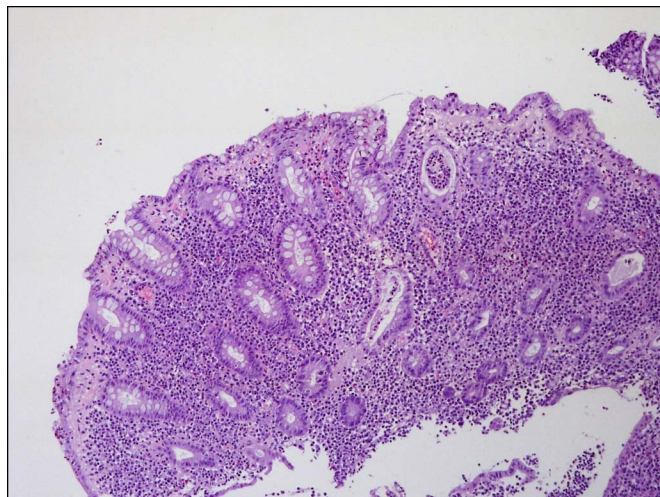
methylprednisolone (48 mg/day) and oral and topical mesalamine treatment. He was discharged with a 4 mg weekly steroid dose reduction (after second weeks of oral steroid therapy) and follow-up plan. The patient was on both clinical and endoscopic remission on the sixth week of the treatment. Figure 4 shows the first-month follow-up rectosigmoidoscopy in which remission.

## DISCUSSION

We present a patient with newly diagnosed UC, whose symptoms started 2 days after the administration of the second dose of BNT162b2 COVID-19 vaccine in a 49-year-old man without a history of autoimmune disease. Localized injection

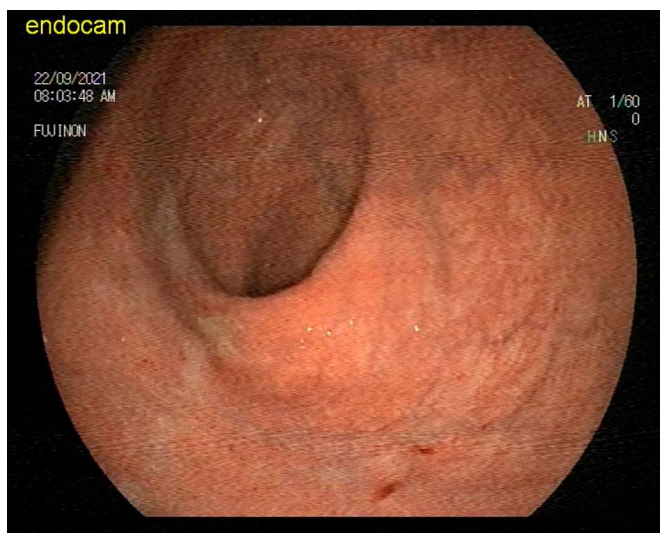


**Figure 2.** The appearance of crypt structures with crypt distortion in histopathological evaluation (H&E 100×). H&E, hematoxylin and eosin; 100×, microscope 100× magnification.



**Figure 3.** The appearance of PMN leukocytes in the surface epithelium (epithelitis), PMN leukocytes (cryptitis) in the crypt epithelium, and PMN leukocyte clusters (crypt abscesses) in the crypt lumen in the histopathological evaluation (H&E 100×). PMN, polymorphonuclear; H&E, hematoxylin and eosin; 100×, microscope 100× magnification.

site reactions and systemic adverse effects can occur after the administration of the different COVID-19 vaccines. Systemic events include fatigue, fever, chills, headache, and myalgias.<sup>6</sup> RNA vaccines have been principally designed for cancer and infectious diseases. This innovative therapeutic approach is based on the synthesis of RNA chains coding for desired antigenic proteins and exploits the intrinsic immunogenicity of nucleic acids. To avoid degradation by RNases, RNA can be encapsulated in nanoparticles or liposomes, which deliver the cargo inside target cells after a process of endocytosis. mRNA is then translated into immunogenic proteins by cell ribosomal machinery.<sup>7</sup> The result is the activation of several proinflammatory cascades, including the assembly of inflammasome



**Figure 4.** Mild hyperemia of the mucosa and appearance of submucosal vascular pattern in colonoscopy examination.

platforms, the type I interferon (IFN) response, and the nuclear translocation of the transcription factor nuclear factor (NF-kappaB).<sup>8</sup> Importantly, the upregulation of these immunological pathways is widely considered to be at the basis of several immune-mediated diseases, especially in genetically predisposed subjects who have an impaired clearance of nucleic acids.<sup>9</sup> IFN- $\alpha$  tends to stimulate T-helper 1 cells, which play a key role in the pathogenesis of various immune-mediated disorders.<sup>10</sup> Chronic mucosal inflammation in inflammatory bowel disease results from hyperactivation of effector immune cells, producing high levels of proinflammatory cytokines such as tumor necrosis factor- $\alpha$ , interleukin-6, and interferon- $\gamma$ , resulting in colonic tissue damage. NF-kappaB is identified as one of the key regulators in this immunological environment. Its activation is markedly induced in patients with inflammatory bowel disease, and through its ability to promote expression of various proinflammatory genes, NF-kappaB strongly influences the course of mucosal inflammation.<sup>11</sup> In addition, multiple cases of chronic hepatitis C infection who developed de novo UC after receiving IFN- $\alpha$ -based therapy have been reported.<sup>12–14</sup> Recently, a case of vitiligo developing after BNT162b2 vaccine was reported in a patient with UC.<sup>15</sup> In addition, a case of newly diagnosed UC was reported that required colectomy after mRNA-1273 vaccine.<sup>16</sup> In our case, the findings of chronicity (epithelitis, cryptitis, crypt abscess, architectural damage, basal plasmacytosis, and crypt atrophy) in the histopathology suggested that the patient had a predisposition to UC. We did not find any reported cases with newly diagnosed UC after BNT162b2 vaccination. BNT162b2 vaccine may have caused exacerbation of UC after activation of NF-kappaB and IFN- $\alpha$ .

This case is the first case of newly diagnosed UC after BNT162b2 vaccination; however, a causality relationship cannot be proven. The clinical significance of this needs to be further evaluated, and individuals presenting with symptoms after mRNA vaccines should be thoroughly investigated.

## DISCLOSURES

**Author contributions:** Ç. Ak wrote and approved the manuscript. S. Sayar reviewed the literature. G. Adalı provided the images and edited the manuscript. K. Özdil revised the manuscript for intellectual content and is the article guarantor.

**Financial disclosure:** None to report.

**Informed consent** was obtained for this case report.

Received October 23, 2021; Accepted March 21, 2022

## REFERENCES

1. WHO. Weekly epidemiological update—March 9, 2021. (<https://www.who.int/publications/m/item/weekly-epidemiological-update-10-march-2021>). Accessed March 15, 2021.
2. Randolph HE, Barreiro LB. Herd immunity: Understanding COVID-19. *Immunity*. 2020;52(5):737–41.
3. WHO. Draft landscape of COVID-19 candidate vaccines. (<https://www.who.int/publications/m/item/draft-landscape-of-covid-19-candidate-vaccines>). Accessed March 4, 2021.
4. Ho W, Gao M, Li F, et al. Next-generation vaccines: Nanoparticle-mediated DNA and mRNA delivery. *Adv Healthc Mater*. 2021;10(8):e2001812.
5. Ghilmetti M, Schaufelberger HD, Mieli-Vergani G, et al. Acute autoimmune-like hepatitis with atypical anti-mitochondrial antibody after mRNA COVID-19 vaccination: A novel clinical entity?. *J Autoimmun*. 2021;123:102706.
6. Shimabukuro TT, Cole M, Su JR. Reports of anaphylaxis after receipt of mRNA COVID-19 vaccines in the US—December 14, 2020–January 18, 2021. *JAMA*. 2021;325(11):1101–2.
7. Marć MA, Domínguez-Álvarez E, Gamazo C. Nucleic acid vaccination strategies against infectious diseases. *Expert Opin Drug Deliv*. 2015;12(12):1851–65.
8. Reikine S, Nguyen JB, Modis Y. Pattern recognition and signaling mechanisms of RIG-I and MDA5. *Front Immunol*. 2014;5:342.
9. Pelka K, Shibata T, Miyake K, et al. Nucleic acid-sensing TLRs and autoimmunity: Novel insights from structural and cell biology. *Immunol Rev*. 2016;269(1):60–75.
10. Tilg H. New insights into the mechanisms of interferon alfa: An immunoregulatory and anti-inflammatory cytokine. *Gastroenterology*. 1997;112(3):1017–21.
11. Atreya I, Atreya R, Neurath MF. NF-kappaB in inflammatory bowel disease. *J Intern Med*. 2008;263(6):591–6.
12. Villa F, Rumi MG, Signorelli C, et al. Onset of inflammatory bowel diseases during combined alpha-interferon and ribavirin therapy for chronic hepatitis C: Report of two cases. *Eur J Gastroenterol Hepatol*. 2005;17(11):1243–5.
13. Mavrogiannis C, Papanikolaou IS, Elefsiniotis IS, et al. Ulcerative colitis associated with interferon treatment for chronic hepatitis C. *J Hepatol*. 2001;34(6):964–5.
14. Sprenger R, Sagmeister M, Offner F. Acute ulcerative colitis during successful interferon/ribavirin treatment for chronic hepatitis. *Gut*. 2005;54(3):438–9.
15. Aktas H, Ertuğrul G. Vitiligo in a COVID-19-vaccinated patient with ulcerative colitis: Coincidence? *Clin Exp Dermatol*. 2022;47(1):143–4.
16. Kothadia S, Ward C, Akerman P. S2424 New diagnosis of severe ulcerative colitis immediately following mRNA-1273 SARS-CoV2 vaccination. *Am J Gastroenterol*. 2021;116:S1027.

**Copyright:** © 2022 The Author(s). Published by Wolters Kluwer Health, Inc. on behalf of The American College of Gastroenterology. This is an open access article distributed under the terms of the Creative Commons Attribution-Non Commercial-No Derivatives License 4.0 (CCBY-NC-ND), where it is permissible to download and share the work provided it is properly cited. The work cannot be changed in any way or used commercially without permission from the journal.